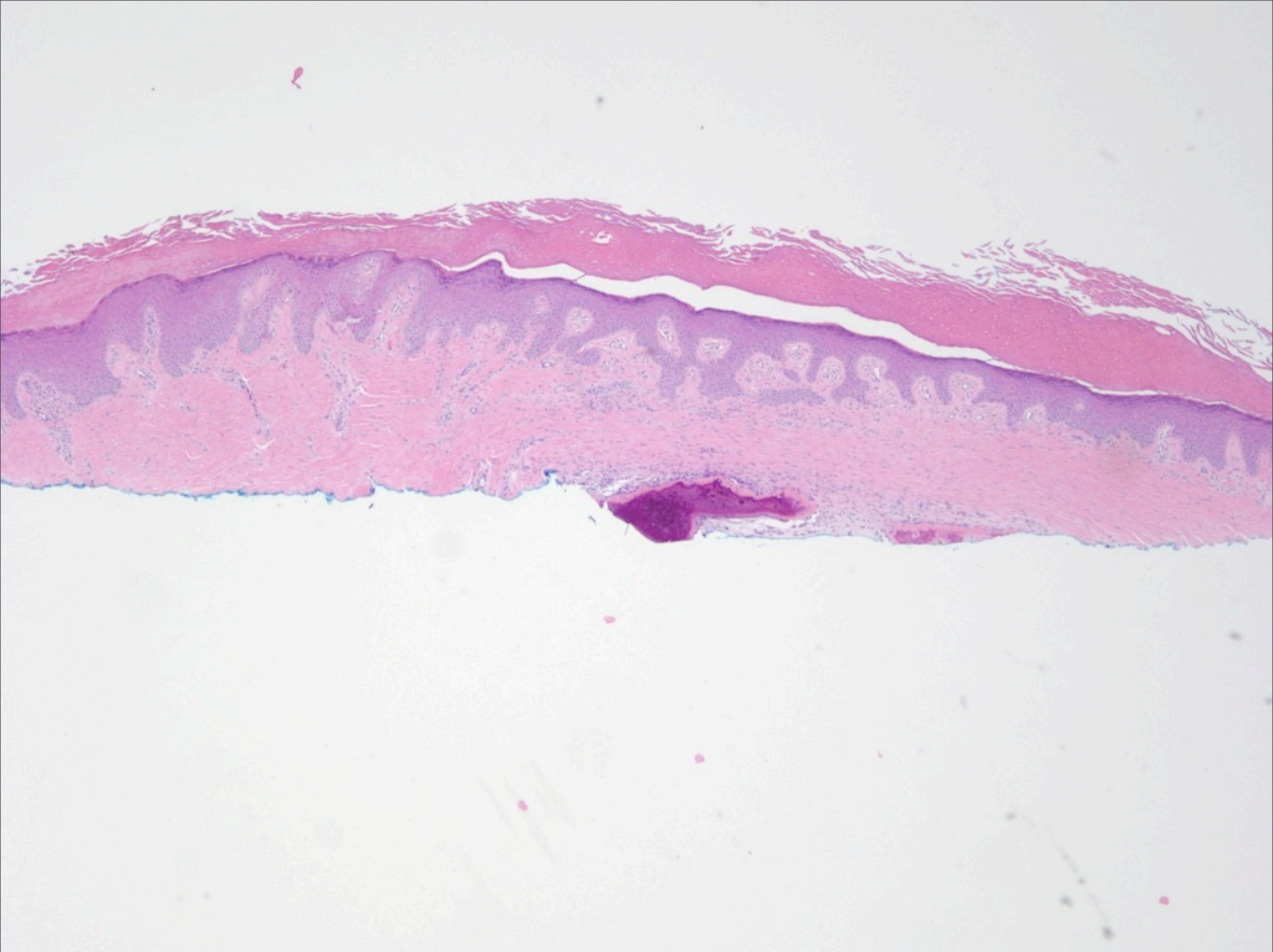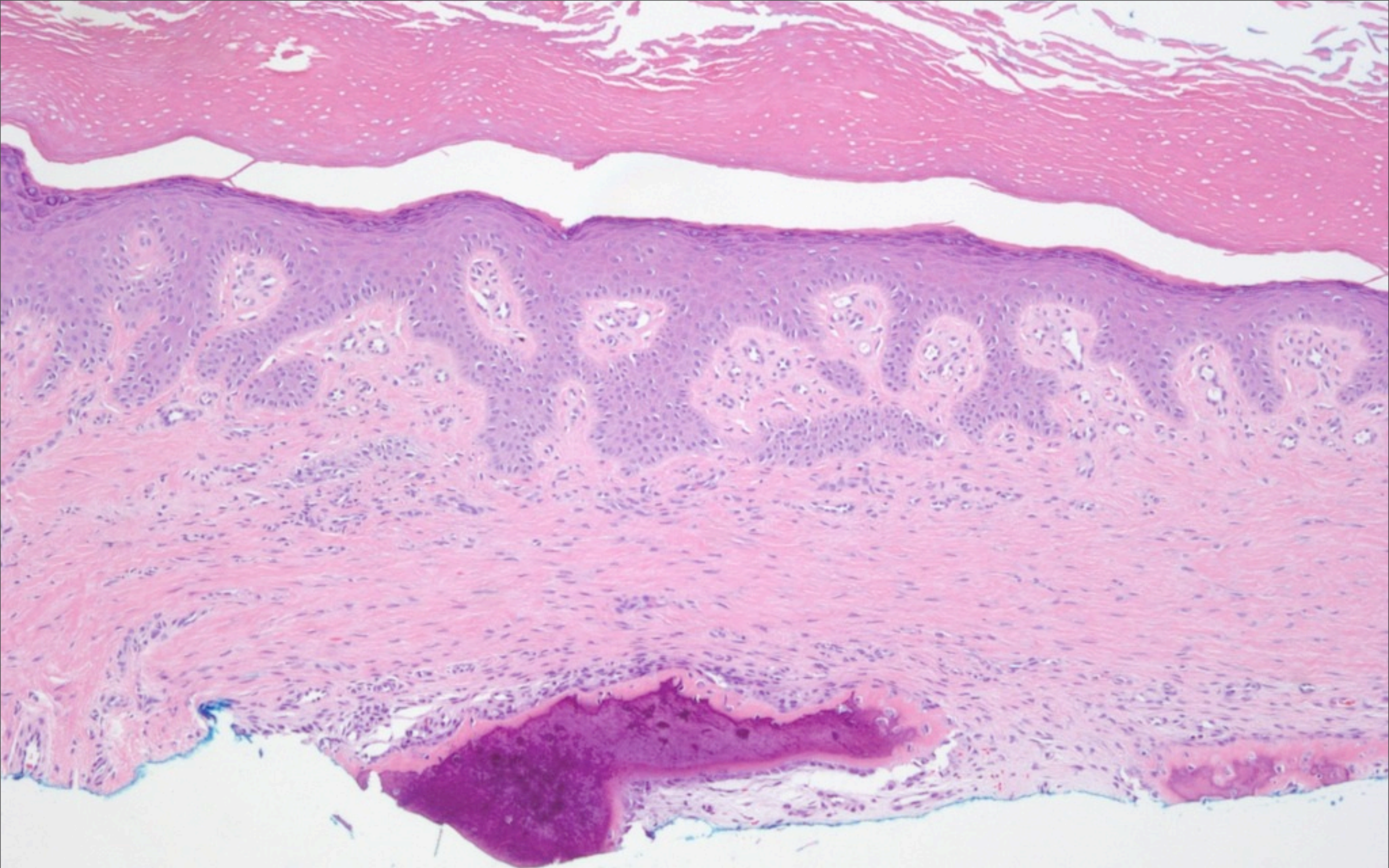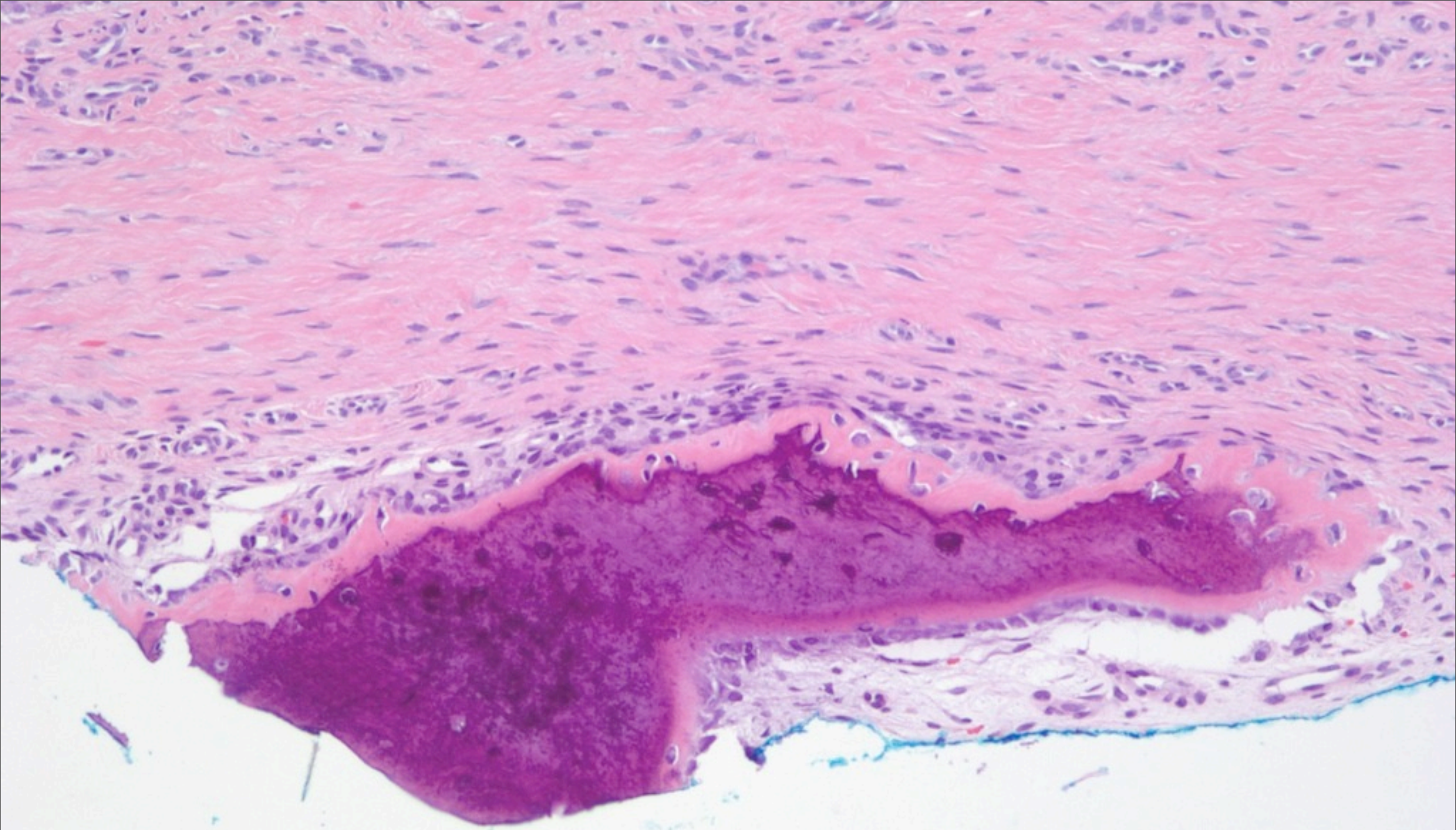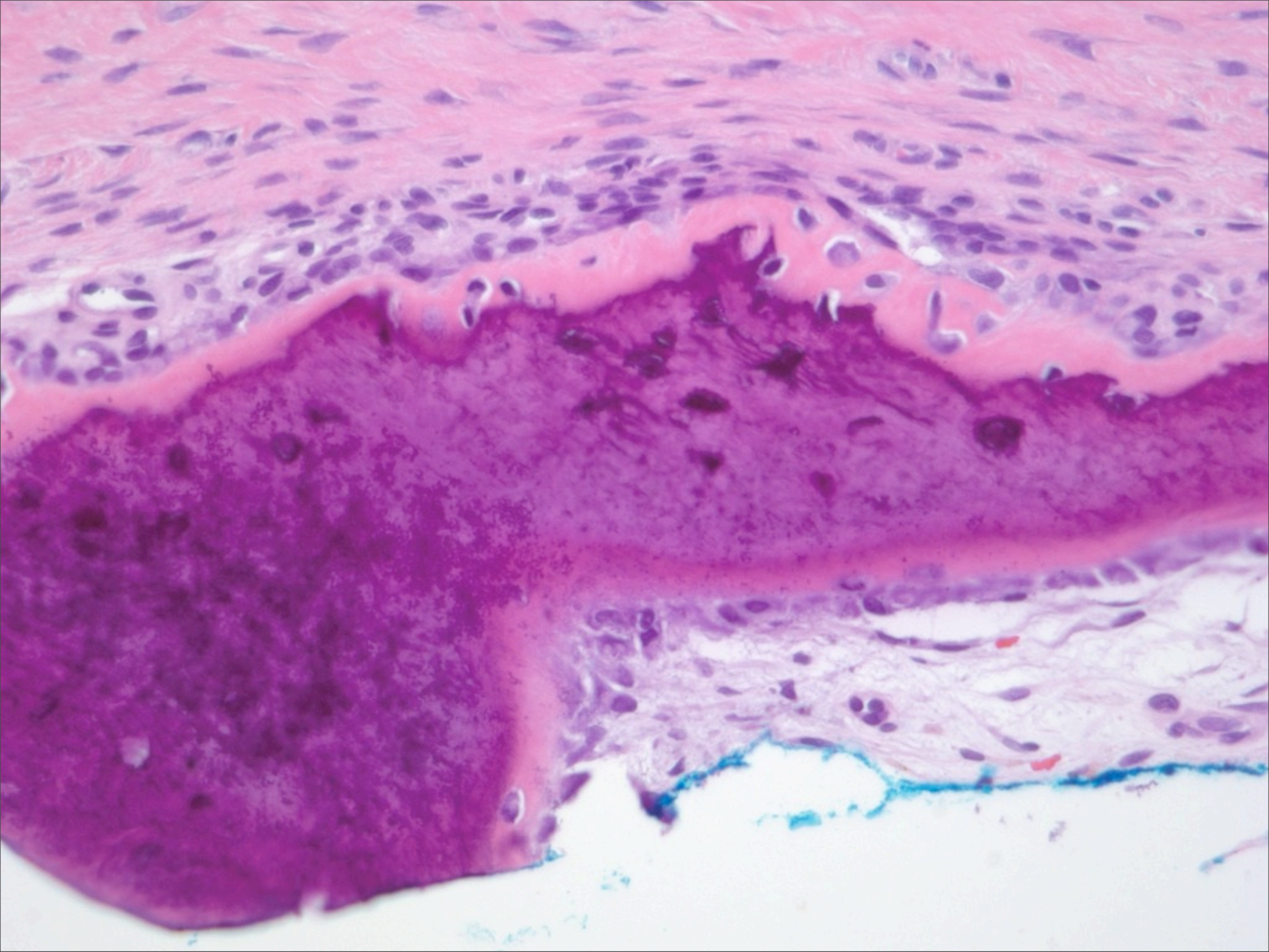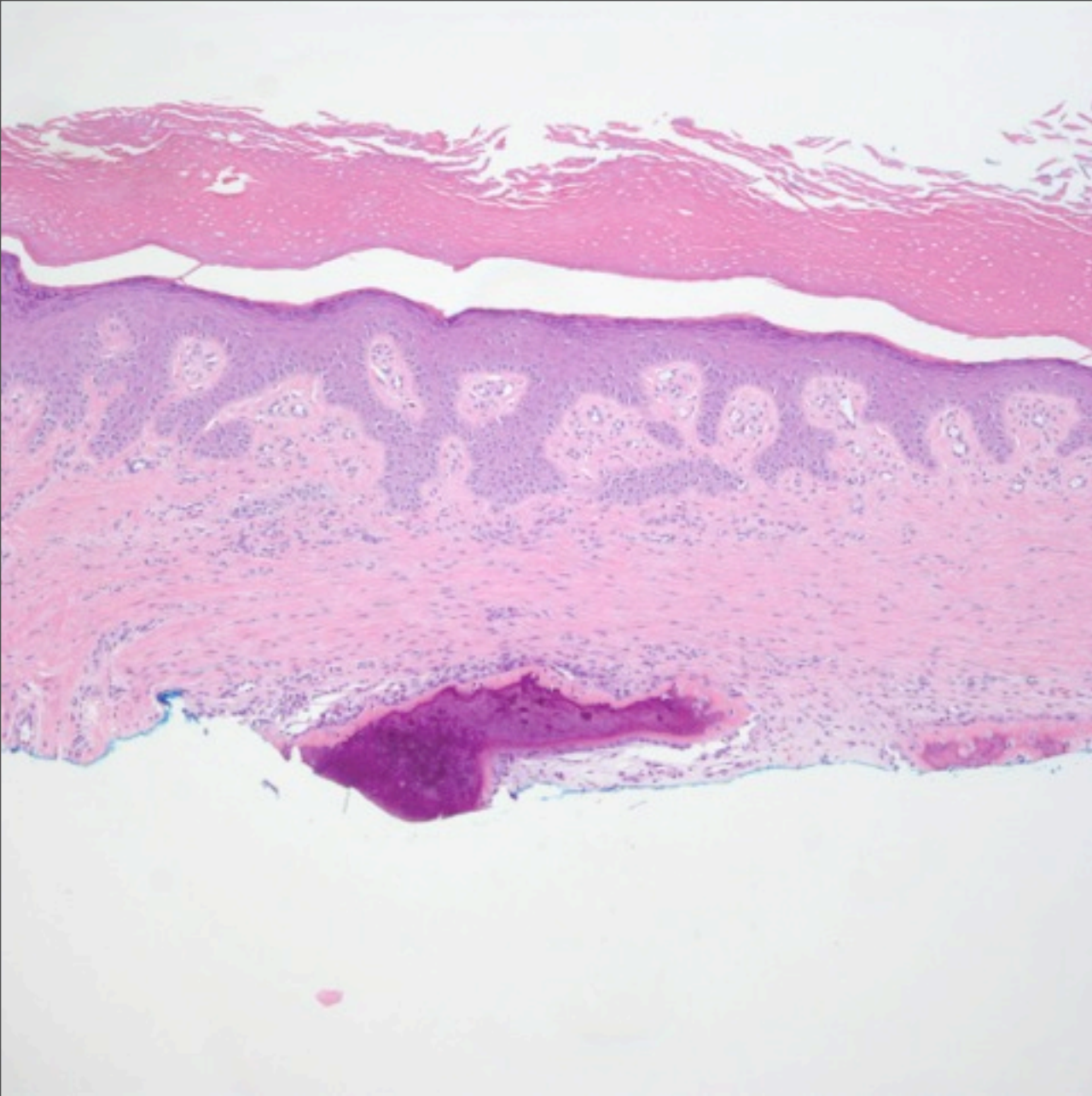


Osteoma Cutis

Look for secondary causes
such as scar, hemangioma,
neoplastic proliferations



Mature Bone with Calcification